



PATIENT

Gracie Mullen

SPECIES

Canine

BREED

Golden Retriever

SEX

Female

AGE

9 months

WEIGHT

56lbs

INTERPRETED BY

Maggie Machen Lamy,
DVM, DACVIM
(Cardiology)

IMAGING PERFORMED BY

Hougentogler, DVM

HOSPITAL NAME

K-Vet Animal Care

REFERRING VET

Dr. Hougentogler

INVOICE

46949

DATE

2/24/26

PRESENTING CLINICAL SIGNS

History: Abnormal breathing after exercise. Elevated BNP: 1084. Physical exam unremarkable.
BP with doppler: 150, 110, 120, 110mmHg

RADIOGRAPHIC FINDINGS *NOTE: Images submitted for supplemental cardiac information only.

Normal cardiac silhouette. No obvious evidence of CHF.

ELECTROCARDIOGRAPHIC FINDINGS

A six lead ECG is available at 25mm/s; 10mm/mV. The average heart rate is 120bpm. The rhythm is sinus in origin, with a p for every QRS complex and vice versa. The P wave morphology is positive with a normal dimension. Normal PR. The QRS morphology is positive with normal dimension. MEA is normal. No ectopic beats, pauses or dysrhythmias observed.

ECG diagnosis: Normal sinus rhythm with respiratory variation.

ECHOCARDIOGRAM FINDINGS

2D, m-mode, color flow and doppler imaging is available. Normal mitral valve leaflets with no prolapse into the left atrial lumen. No mitral regurgitation is seen, with a normal left atrial dimension. Normal LV diameter with adequate myocardial function. The tricuspid valve appears normal with no significant tricuspid regurgitation. Normal right atrial and ventricular diameter and morphology indicating no overt evidence of pulmonary arterial hypertension. The pulmonic and aortic valves are normal in morphology and mobility. Normal pulmonic and mildly elevated aortic outflow velocities with laminar flow. No aortic and trace pulmonic insufficiency. No obvious congenital shunts or defects are observed. No pericardial or pleural effusion noted. No obvious cardiac masses.

CARDIAC CHART

CANINE CARDIAC PARAMETERS	MR VMAX (m/s)	TR VMAX (m/s)	LA/AO (Boon method)	LA/AO (Heart Base; Swe)	FS (%)	EF (%)	EPSS (cm)
NORMAL PARAMETER	4.5-5.5	<2.7	1.3	<1.6	28-40	40-100	<0.6
PATIENT	NA	NA	1.3	1.2	28	50	0.4
CANINE CARDIAC PARAMETERS	HR (BPM)	AV VMAX (m/s)	PV MAX (m/s)	BODY WEIGHT (kg)	LA 2D short axis Base view (cm)	LVIDd Avg; 2D and m-mode short axis (cm)	LVIDs Avg; 2D and m-mode short axis (cm)
NORMAL PARAMETER	50-100	0.7-1.7	0.7-1.6	BELOW	BELOW	BELOW	BELOW
PATIENT	NM	2.2	1.3	25.4	2.5	4.2	3.0
*Normal chamber parameters expressed as a mean value (SD)				3	1.27 (5.3)	2.46 (2.46)	1.36 (5.5)
BODY WEIGHT DEPENDENT PARAMETERS				5	1.40 (4.5)	2.74 (5.2)	1.60 (4.7)
*Note: All measurements based upon multi-modal images and methods. An average value is reported.				10	1.50 (3.8)	3.27 (3.5)	2.06 (3.1)
				15	1.83 (2.0)	3.71 (2.4)	2.43 (2.1)
				20	2.02 (1.9)	4.14 (2.2)	2.80 (2.0)
				25	2.18 (2.4)	4.48 (2.9)	3.10 (2.5)
				30	2.33 (3.3)	4.83 (3.9)	3.39 (3.4)
				35	2.48 (4.3)	5.17 (5.0)	3.69 (4.5)
				40	2.62 (5.2)	5.48 (6.1)	3.96 (5.4)
				50	2.88 (7.1)	6.07 (8.3)	4.46 (7.4)

Adapted from June Boon, Veterinary Echocardiography, 1998
Rishniw M and Hollis NE, J Vet Intern Med 2000; 14:429-435
Hansson et al, Vet Rad and Ultrasound 2002
Bonagura et al. Echocardiography: principles of interpretation, Vet Clin North Am 15:1177, 1995



PATIENT

Gracie Mullen

SPECIES

Canine

BREED

Golden Retriever

SEX

Female

AGE

9 months

WEIGHT

56lbs

INTERPRETED BY

Maggie Machen Lamy,
DVM, DACVIM
(Cardiology)

IMAGING PERFORMED BY

Hougentogler, DVM

HOSPITAL NAME

K-Vet Animal Care

REFERRING VET

Dr. Hougentogler

INVOICE

46949

DATE

2/24/26

INTERPRETATION OF THE FINDINGS & FURTHER RECOMMENDATIONS

Overtly normal cardiac structural and function is identified. No significant valve leaks are appreciated, and no significant stenosis appreciated. A mildly elevated aortic outflow velocity is noted, which in the absence of stenosis is considered a benign flow abnormality that may cause a soft murmur in the future. No obvious congenital issues are seen and in the absence of a heart murmur structural disease is highly unlikely. The ECG is unremarkable with a normal sinus rhythm.

These findings would suggest exercise-induced breathing changes are certainly non-cardiogenic in origin. Further workup may be warranted. Additionally, no cause for BNP elevation is seen here. In an otherwise young healthy dog, a false positive is suspected.

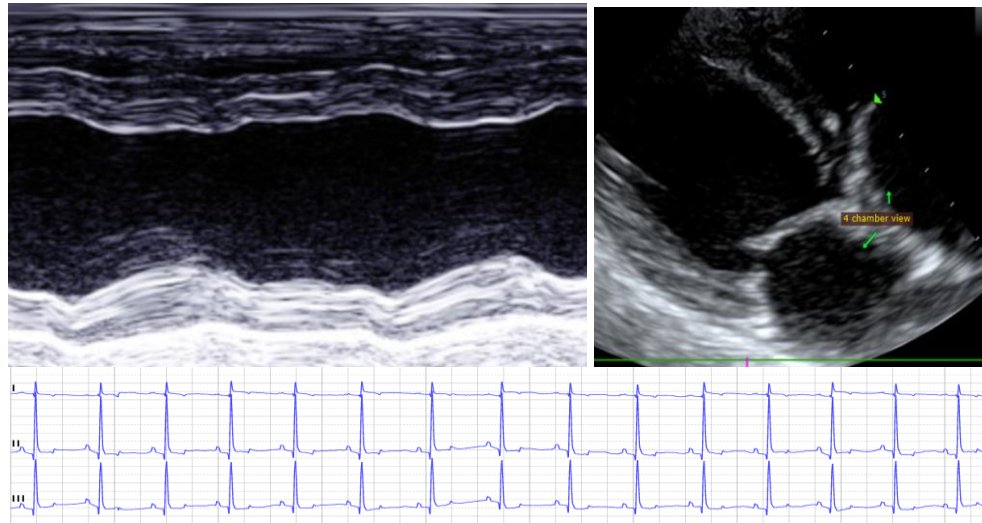
No obvious contraindication for breeding this animal. It should be noted that an OFA evaluation by an attending Cardiologist is the gold standard breed screening exam and should be considered in this animal (congenital evaluation in addition to annual monitoring for development of cardiomyopathy).

Prognosis is open and there is no contraindication for general anesthesia.

Monitor for development of a heart murmur, cough, labored breathing, exercise intolerance or collapse episodes.

A recheck echocardiogram is recommended annually for breeding soundness, sooner if any clinical signs, murmur, etc. arise.

IMAGES



The information and recommendations provided are based on the images presented by the referring veterinarian. No evaluation can be communicated regarding pathology that was not visible in the image/video clips provided.



PATIENT

Gracie Mullen

SPECIES

Canine

BREED

Golden Retriever

SEX

Female

AGE

9 months

WEIGHT

56lbs

INTERPRETED BY

Maggie Machen Lamy,
DVM, DACVIM
(Cardiology)

IMAGING PERFORMED BY

Hougentogler, DVM

HOSPITAL NAME

K-Vet Animal Care

REFERRING VET

Dr. Hougentogler

INVOICE

46949

DATE

2/24/26

Thank you for this referral. This report was generated using transcription software, and minor dictation errors may be present. If the clinical or image interpretation does not parallel your findings or if I can be of any further assistance, please contact me.

Maggie Machen Lamy, DVM

Diplomate of the American College of Veterinary Internal Medicine (Cardiology)

info@sonopath.com